

PennHIP Report

Referring Veterinarian: Dr Courtenay Large
Email: courtenay.large@vca.com

Clinic Name: Island Animal Hospital
Clinic Address: 1800 Bowen Road
Nanaimo, BC V9S 5W4
Phone: (250) 753-1288
Fax: (250) 753-1218

Patient Information

Client: Hrad, Ellen
Patient Name: Stoney River's Mr Buddy (Ted)
Reg. Name:
PennHIP Num: 146323
Species: Canine
Date of Birth: 01 Jan 2017
Sex: Male
Date of Study: 28 Aug 2020
Date of Report: 03 Sep 2020

Tattoo Num:
Patient ID: 62907
Registration Num:
Microchip Num: 956000005423672
Breed: STANDARD POODLE
Age: 43 months
Weight: 58 lbs/26.3 kgs
Date Submitted: 02 Sep 2020

Findings

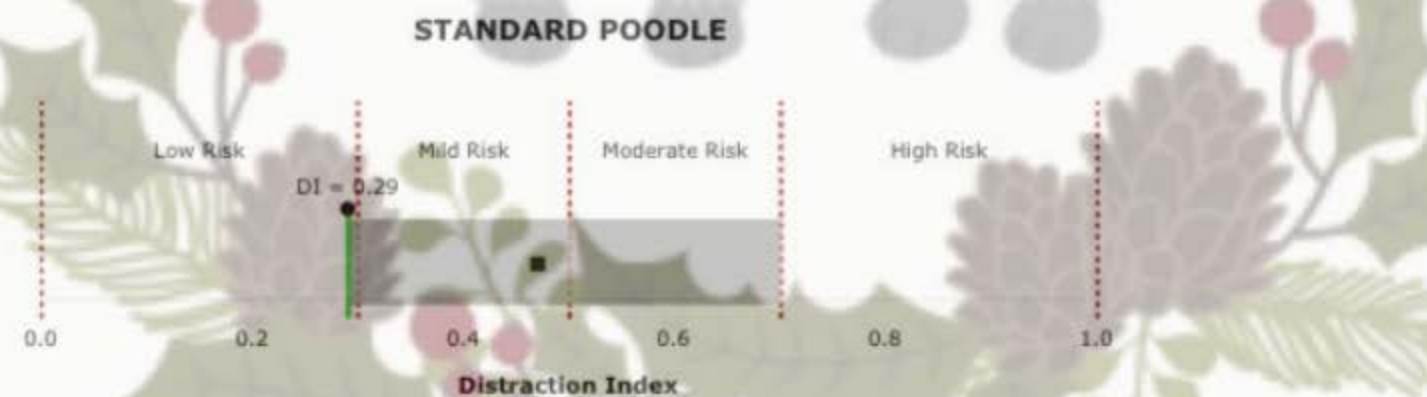
Distraction Index (DI): Right DI = 0.29, Left DI = 0.24.
Osteoarthritis (OA): No radiographic evidence of OA for either hip.
Cavitation/Other Findings: No cavitation present.

Interpretation

Distraction Index (DI): The laxity ranking is based on the hip with the greater laxity (larger DI). In this case the DI used is 0.29.

OA Risk Category: The DI is less than or equal to 0.30. This patient is at minimal risk for hip OA.

Distraction Index Chart:



BREED STATISTICS: This interpretation is based on a cross-section of 4044 canine patients of the STANDARD POODLE breed in the AIS PennHIP database. The gray strip represents the central 90% range of DIs (0.29 - 0.70) for the breed. The breed average DI is 0.47 (solid square). The patient DI is the solid circle (0.29).

SUMMARY: The degree of laxity (DI = 0.29) ranks the hip within the tightest 5% of DIs for the breed. This amount of hip laxity places the hip at a minimal risk to develop hip OA. No radiographic evidence of OA for either hip.